

## When *E. Faecalis* strikes beyond the globe: Orbital cellulitis requiring exenteration

Eduardo Bianchi<sup>1</sup>, Nicola De Santi<sup>2</sup>, Davide Tucci<sup>2</sup>, Michael Spinosi<sup>2</sup>, Francesco Giovacchini<sup>2</sup>

From <sup>1</sup>Resident, <sup>2</sup>Consultant, Department of Ophthalmology, Department of Maxillo-Facial Surgery, University of Perugia, University of Perugia, Perugia, Italy

### ABSTRACT

We report the case of an 80-year-old woman affected by *Enterococcus faecalis* endophthalmitis complicated by orbital cellulitis. Despite maximal medical therapy, including topical fortified antibiotics, intravitreal injections, and intravenous systemic treatment, infection control was not achieved, and the condition progressed into an orbital abscess with worsening proptosis and ophthalmoplegia. Considering the lack of visual potential and the imminent risk of intracranial spread, a subtotal orbital exenteration was performed. Reconstruction was achieved with a vascularized temporalis muscle flap through a transorbital approach. This case highlights the aggressive nature of *E. faecalis* ocular infections and supports exenteration as a life-saving measure when conventional therapy fails.

**Key words:** Cellulitis, Endophthalmitis, *Enterococcus faecalis*, Orbit

Endophthalmitis is a purulent intraocular infection that can arise from surgical, traumatic, or endogenous causes and represents one of the most feared complications in ophthalmic surgery [1]. The reported incidence after cataract extraction varies between 0.02% and 0.2%, depending on geographic region, surgical technique, and prophylactic measures used [2]. Large population-based studies in the United States and Sweden have estimated an average incidence of 0.05–0.09% following cataract surgery [3,4]. Among culture-positive cases, *Enterococcus* species account for approximately 2–5%, with *Enterococcus faecalis* being the most frequently isolated species [5,6]. In the Endophthalmitis Vitrectomy Study, *Enterococcus* represented 2.2% of all culture-positive isolates [7]. Therefore, the estimated overall incidence of *E. faecalis* endophthalmitis following intraocular surgery ranges from 0.0004% to 0.005%, corresponding to 0.4–5 cases per 100,000 procedures [8]. Despite its rarity, *E. faecalis* infection is notable for rapid retinal destruction, poor visual prognosis, and relative resistance to antimicrobial therapy [9]. Orbital cellulitis secondary to intraocular infection is extremely uncommon but can lead to life-threatening complications, such as meningitis, intracranial abscess, or cavernous sinus thrombosis [10,11]. The combination of *E. faecalis* endophthalmitis and orbital cellulitis is particularly rare, with only a few cases described in the literature [12,13].

Reporting this case is crucial to highlight the diagnostic and therapeutic challenges posed by this infection and to emphasize the potential life-saving role of early exenteration with vascularized flap reconstruction.

### CASE PRESENTATION

An 80-year-old woman presented with a 5-day history of redness, swelling, and severe pain in the right eye, unresponsive to topical self-medication with betamethasone 0.2 mg/mL and chloramphenicol 0.5 mg/mL. Her medical history included insulin-dependent diabetes mellitus, psoriatic arthritis, and a penetrating keratoplasty for keratoconus performed 12 years prior. The last documented visual acuity in the right eye was limited to light perception. On admission, vital parameters were as follows: Temperature 38.2°C, blood pressure 150/85 mmHg, heart rate 96 beats/min, respiratory rate 20/min, and oxygen saturation 97% on room air.

Clinical examination revealed marked eyelid edema, conjunctival chemosis, and diffuse hyperemia. The corneal graft was opaque, with residual sutures and a localized temporal corneal abscess (Fig. 1). Fundus visualization was not possible. B-scan ultrasonography demonstrated vitreous opacities with membranous hyperechogenic echoes and chorioretinal thickening (Fig. 2). Non-contrast orbital computed tomography (CT) showed right-sided exophthalmos, diffuse orbital soft tissue swelling, an enlarged lacrimal gland, and

#### Access this article online

Received - 16 October 2025  
Initial Review - 30 October 2025  
Accepted - 24 November 2025

#### Quick Response code



DOI: 10.32677/ijcr.v11i12.7904

**Correspondence to:** Eduardo Bianchi, Resident, Department of Ophthalmology, Department of Maxillo-Facial Surgery, Perugia, Italy. E-mail: drbianchieduardo@libero.it

© 2025 Creative Commons Attribution-NonCommercial 4.0 International License (CC BY-NC-ND 4.0).

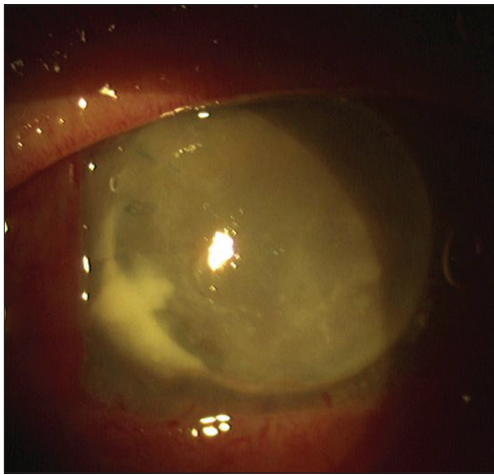


Figure 1: Right eye at presentation

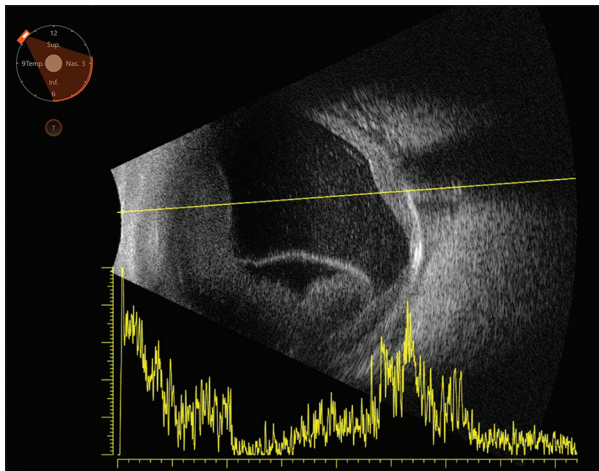


Figure 2: ECO-AB scan

poorly differentiated anterior and posterior segments. Vitreous aspirate culture was positive for *E. faecalis*, sensitive to vancomycin, while blood cultures and nasal swabs were negative.

The patient received intravitreal vancomycin (1 mg/0.1 mL) and ceftazidime (2 mg/0.1 mL), along with hourly fortified topical vancomycin (50 mg/mL) and tobramycin (9–14 mg/mL). Systemic intravenous therapy included vancomycin 1 g every 12 h and piperacillin/tazobactam 4.5 g every 8 h. After transient improvement, corneal dehiscence and perforation occurred within 72 h, accompanied by worsening proptosis and complete ophthalmoplegia. Magnetic resonance imaging (MRI) with contrast revealed diffuse orbital inflammation with a fusiform abscess adjacent to the lateral rectus muscle and enhancement of the optic nerve (Fig. 3), consistent with Chandler stage IV orbital cellulitis [11].

Given the lack of visual potential, persistent infection, and high risk of intracranial extension, the patient underwent subtotal orbital exenteration under general anesthesia. The orbital contents were removed within the periosteum up to the apex, and meticulous hemostasis and disinfection were performed. Reconstruction was achieved with a vascularized temporalis muscle flap, mobilized through a lateral orbital osteotomy while preserving the orbital rim for structural support. The muscle was anchored within the anophthalmic cavity,

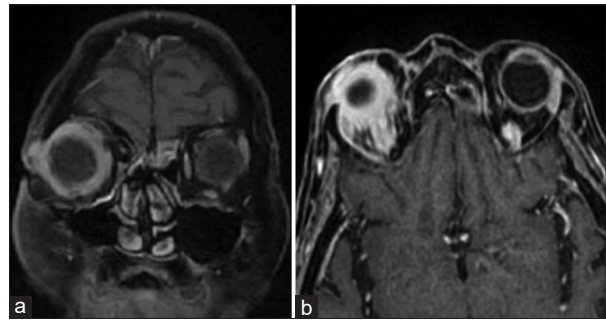


Figure 3: Magnetic resonance imaging with medical dye contrast. (a) Supero-lateral abscess. (b) Optic neuritis

allowing preservation of the eyelids and restoration of facial contour. This reconstructive approach is well established for providing vascularized tissue coverage and favorable cosmetic outcomes [14,15].

Post-operatively, systemic and local infection parameters normalized within 5 days. The eyelids were preserved, and the patient achieved a satisfactory cosmetic result, although mild temporal hollowing was noted. Follow-up MRI at 2 months demonstrated complete resolution of the abscess and no evidence of residual infection. No systemic or intracranial complications developed during 6 months of follow-up.

## DISCUSSION

*E. faecalis* is a Gram-positive facultative anaerobe that represents a rare but highly virulent cause of post-operative endophthalmitis. Its pathogenicity is primarily mediated by cytolysin, a pore-forming toxin that causes rapid retinal necrosis and significant loss of electrophysiological function, as documented by a marked reduction of the electroretinogram b-wave within 24–36 h of infection [16–18]. In addition, *E. faecalis* expresses aggregation substance and adhesins, which promote biofilm formation and intraocular sequestration, rendering antibiotic therapy less effective [19]. This explains why, even with aggressive intravitreal vancomycin, ceftazidime, and systemic therapy, the infection may progress to orbital extension.

A review of the literature reveals few cases of *E. faecalis* endophthalmitis with orbital cellulitis. Hesse *et al.* [12] reported post-operative enterococcal endophthalmitis requiring evisceration due to orbital involvement, while Chen *et al.* [6] observed rapid progression and poor visual outcomes despite early vitrectomy and targeted antibiotics. Pijl and Theelen [20] and Khan *et al.* [21] recently highlighted the importance of early recognition and surgical intervention to prevent intracranial spread. Our case confirms the need for a multidisciplinary approach involving ophthalmologists, maxillofacial surgeons, and infectious disease specialists.

Therapeutic challenges arise not only from bacterial virulence but also from anatomical and physiological barriers within the eye and orbit. Intraocular biofilms and bacterial sequestration in microanatomic pockets impede drug penetration, while orbital edema may reduce vascular

supply, limiting systemic antibiotic delivery [19,22]. Differential diagnosis in this setting includes infections by *Staphylococcus aureus*, *Streptococcus pyogenes*, *Pseudomonas aeruginosa*, and fungal pathogens, such as *Mucor* and *Aspergillus*, particularly in immunocompromised patients [10,11,22,23]. Imaging, clinical presentation, and microbiological studies are crucial to distinguish these entities, as treatment strategies differ markedly.

Surgical intervention is often required when infection extends beyond the globe. Orbital exenteration, though traditionally reserved for malignancy, may be life-saving in cases of extensive abscess formation or risk of intracranial dissemination [24]. Early intervention reduces bacterial load, prevents systemic spread, and allows for reconstructive procedures. The temporalis muscle flap, as described by Bhattacharjee *et al.* [14] and Nassab *et al.* [15], provides vascularized tissue coverage, enhances local antibiotic delivery, and yields favorable cosmetic results while preserving eyelid integrity. In our patient, this approach ensured both infection control and acceptable esthetic outcomes.

Clinically, this case underscores the importance of vigilant monitoring of high-risk patients, particularly elderly diabetics with previous ocular surgery, to promptly identify signs of orbital involvement. The combination of careful clinical evaluation, imaging studies, and microbiological confirmation allows for timely decision-making regarding medical versus surgical management. Literature review suggests that, although rare, *E. faecalis* endophthalmitis with orbital extension carries a high risk of visual loss and potentially life-threatening complications, making early intervention essential [6,12,20,21].

## CONCLUSION

*E. faecalis* endophthalmitis may progress rapidly to orbital cellulitis and abscess despite maximal antimicrobial therapy. Subtotal orbital exenteration with temporalis muscle flap reconstruction represents an effective, life-saving strategy in cases refractory to medical management. Early multidisciplinary evaluation and prompt surgical intervention are critical to prevent intracranial complications and ensure patient survival.

## AUTHORS' CONTRIBUTIONS

EB, NS, and DT: Wrote the case and followed the eye condition, MS and FS: Followed the orbital infection, MS: Performed the exenteration orbitae.

## REFERENCES

1. Durand ML. Endophthalmitis. Clin Microbiol Infect 2017;23:423-30.
2. Taban M, Behrens A, Newcomb RL, Nobe MY, Saedi G,

3. Sweet PM, *et al.* Acute endophthalmitis following cataract surgery: A systematic review of the literature. Ophthalmology 2005;112:2133-41.
4. Barry P, Seal DV, Gettinby G, Lees F, Peterson M, Revie CW, *et al.* Intracameral antibiotic prophylaxis: American paper mirrors European experience. Ophthalmology 2013;120:2411-20.
5. Friling E, Lundström M, Stenevi U, Montan P. Post-cataract endophthalmitis in Sweden 2005-2017. Acta Ophthalmol 2019;97:860-6.
6. Han DP, Wisniewski SR, Wilson LA, Barza M, Vine AK, Doft BH, *et al.* Spectrum and susceptibilities of microbiologic isolates in the EVS. J Ophthalmic Inflamm Infect 2019;9:9.
7. Chen KJ, Lai CC, Chen HC, Chong YJ, Sun MH, Chen YP, *et al.* *Enterococcus faecalis* endophthalmitis: Clinical settings, antibiotic susceptibility, and outcomes. Microorganisms 2021;9:918.
8. EVS Group. Results of the Endophthalmitis Vitrectomy Study. A randomized trial of immediate vitrectomy and of intravenous antibiotics for the treatment of postoperative bacterial endophthalmitis. Endophthalmitis Vitrectomy Study Group. Arch Ophthalmol 1995;113:1479-96.
9. Callegan MC, Engelbert M, Parke DW 2<sup>nd</sup>, Jett BD, Gilmore M. Bacterial endophthalmitis: Epidemiology, therapeutics, and bacterium-host interactions. Clin Microbiol Rev 2002;15:111-24.
10. Durand ML. Bacterial and fungal endophthalmitis. Clin Microbiol Rev 2017;30:597-613.
11. Tsirouki T, Dastiridou AI, Flores NI, Cerpa JC, Moschos MM, Brazitikos P, *et al.* Orbital cellulitis: Clinical features and management. Surv Ophthalmol 2018;63:534-53.
12. Schmitz A, Lecuona K, Rauscher FG, Sand J. Orbital cellulitis: A multidisciplinary emergency. Clin Exp Ophthalmol 2019;47:91-6.
13. Hesse Y, Spraul CW, Lang GK. Enterococcal endophthalmitis following cataract surgery. Klin Monl Augenheilkd 2002;219:109-12.
14. Le Lez ML, Lanotte P, Arsene S. Postoperative *E. faecalis* endophthalmitis. Am J Ophthalmol 2000;129:155-63.
15. Bhattacharjee K, Bhattacharjee H, Singh M. Single-stage socket reconstruction with vascularized temporalis muscle flap following exenteration. Indian J Ophthalmol 2017;65:208-12.
16. Nassab R, Thomas S, Matthews RN. Reconstruction following orbital exenteration using the temporalis muscle flap: A 10-year review. J Plast Reconstr Aesthet Surg 2010;63:758-62.
17. Callegan MC, Booth MC, Jett BD, Gilmore MS. Pathogenesis of Gram-positive bacterial endophthalmitis. Infect Immun 1999;67:3348-56.
18. Horio N, Terasaki H, Yamamoto E, Miyake Y. Electroretinogram in the diagnosis of endophthalmitis after intraocular lens implantation. Am J Ophthalmol 2001;132:258-9.
19. Bron A. Endophthalmies: Le diagnostic. J Fr Ophtalmol 1996;19:225-40.
20. Jett BD, Atkuri RV, Gilmore MS. *Enterococcus faecalis* localization in experimental endophthalmitis: Role of aggregation substance. Infect Immun 1998;62:987-93.
21. Pijl BJ, Theelen T. Clinical characteristics and visual outcome of *E. faecalis* endophthalmitis. Acta Ophthalmol 2020;98:e686-92.
22. Khan Y. Aggressive *Enterococcus faecalis* endophthalmitis leading to orbital abscess: A case and literature review. Eye (Lond) 2023;37:1625-30.
23. Kanski JJ, Bowling B. Clinical ophthalmology: A systematic approach. 8<sup>th</sup> ed. Amsterdam: Elsevier; 2016.
24. Yanoff M, Duker JS. Ophthalmology. 5<sup>th</sup> ed. Amsterdam: Elsevier; 2018.
25. Leatherbarrow B. Oculoplastic Surgery. Berlin: Springer; 2011.

Funding: Nil; Conflicts of interest: Nil.

**How to cite this article:** Bianchi E, De Santi N, Tucci D, Spinosi M, When *E. Faecalis* strikes beyond the globe: Orbital cellulitis requiring exenteration. Indian J Case Reports. 2025;11(12):675-677.