

A rare cause of drop attacks in a young male

Krishnan Balagopal¹, Jain George², Elizabeth Kuruvilla³, Ameen Abdul Khader³, Jobin John³, Nikhil Philip³

From ¹Consultant Neurologist, Department of Neurology, ²Consultant Neurosurgeon, Department of Neurosurgery, ³Junior Resident, Department of Neurology, MOSC Medical College, Kochi, Kerala, India

A drop attack is defined as a sudden fall to the ground without any obvious external cause and also without associated loss of consciousness. Patients usually recover their balance and normal function quickly after a drop attack, though they may sustain injuries from the fall. Causes can vary and include inner ear disorders such as Meniere's disease, atonic seizures, vestibular neuronitis, cardiac valvular disorders, and sometimes functional disorders. Some drop attacks are considered idiopathic, meaning no cause is found after thorough medical evaluation, especially in elderly patients. A colloid cyst is a benign brain tumor in the third ventricle that can cause "drop attacks" by suddenly obstructing the flow of cerebrospinal fluid (CSF) and leading to temporary brainstem compression [1]. We present a case of a young man with headache and drop attacks who was found to have a colloid cyst with hydrocephalus.

This 35-year-old male patient with no prior comorbidities presented with a 3-month history of intermittent occipital headaches associated with neck pain. The pain used to worsen on bending forwards and coughing and used to be worse in the recumbent position. There was no history of associated fever, nausea, or vomiting. He also had two episodes of sudden fall to the ground with buckling of the legs. There was no loss of consciousness, tongue bite, or incontinence. There was no prior history of seizures or family history of epilepsy. General examination and vital signs were normal with no postural fall of blood pressure. Cardiac examination was normal. Neurological examination, including cranial nerves, motor, and sensory examination, was within normal limits. There were no meningeal signs.

Routine blood investigations were within normal limits. An electroencephalogram was done, which showed no abnormalities. Magnetic resonance imaging (MRI) brain showed a large colloid cyst of the third ventricle causing obstruction of the foramina of Monro and hydrocephalus (Figs. 1 and 2). MRI T2 sequences showed a well-defined ovoid cystic lesion measuring 3.9*2.9*3.2 cm expanding the third ventricle and

obstructing the foramen of Monro. The lesion was hyperintense on T2 with hydrocephalus-suggestive of a large colloid cyst of the third ventricle. The cyst was inferiorly abutting the roof of the third ventricle and laterally indenting the lateral ventricular wall.

Neurosurgery opinion was taken, and surgical excision was advised at the earliest. The lesion was approached under microscope through a precoronal midline single burr hole mini craniotomy and a 3 cm dural opening. The surgical corridor was an interhemispheric transcallosal transventricular, transforaminal route. The lesion was identified at the foramen of Monro, which was stretched and completely occupied by the cyst, blocking the third and lateral ventricles. The cyst was initially aspirated to reduce its size to facilitate dissection and complete removal. After removal, the ventricle was filled with saline, the dura closed, and the bone flap secured with a mini plate and screws. The post-operative period was uneventful, and he was discharged after improvement. He is under regular follow-up.

Colloid cysts are mucous-filled masses that are surrounded by an outer fibrous layer. The inner material may contain old blood, cholesterol, and mucin. These cysts are a rare developmental malformation and not neoplastic processes. They are congenital benign tumors accounting for 15–20% of intraventricular masses. However, they constitute only about 1% of intracranial lesions [2]. They can be diagnosed at any age, but usually become symptomatic in the third to sixth decades with a male preponderance. They are usually found incidentally and are asymptomatic. In some cases, they may be associated with rapid neurologic deterioration, herniation, and sudden death [3]. These colloid cysts are usually found near the foramen of Monro in the anterior part of the third ventricle and may interfere with the drainage of the CSF. This may result in hydrocephalus and an increase in intracranial pressure, which may cause frontal and intermittent headaches. Other symptoms of colloid cysts are memory changes, gait unsteadiness, and drop attacks. The typical clinical picture of intermittent headaches and drop is seen only in a third of all patients. Sudden obstruction of the ventricular system and acute hydrocephalus can cause increases in intracranial pressure

Access this article online

Received - 08 September 2025
Initial Review - 24 September 2025
Accepted - 24 October 2025

Quick Response code



DOI: 10.32677/ijcr.v11i12.7849

Correspondence to: Dr. Krishnan Balagopal, Consultant Neurologist, MOSC Medical College, Kochi, Kerala, India. E-mail: krishnan.balagopal@gmail.com

© 2025 Creative Commons Attribution-NonCommercial 4.0 International License (CC BY-NC-ND 4.0).

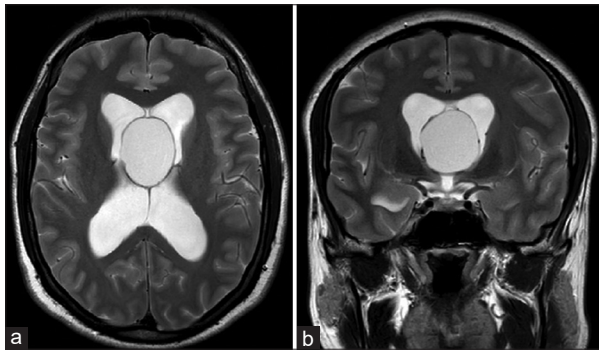


Figure 1: T2 axial (a) and coronal (b) sequences showing a well-defined ovoid cystic lesion measuring 3.9*2.9*3.2 cm expanding the third ventricle and obstructing the foramen of Monro. The lesion is hyperintense on T2 with hydrocephalus-suggestive of a large colloid cyst of third ventricle

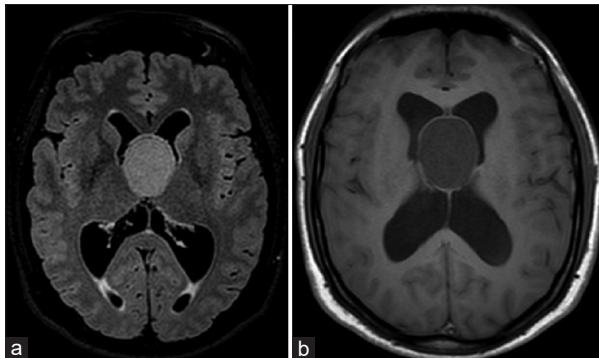


Figure 2: Colloid cyst in the lateral ventricle-hyperintense on T2 fluid-attenuated inversion recovery (a) and hypointense on T1 (b)-inferiorly abutting the roof of third ventricle and laterally indenting the lateral ventricular walls

and even a risk of sudden death due to cardiac arrest [4]. This is the reason why these cysts need to be surgically excised as soon as hydrocephalus develops. Diagnosis of this entity can be made by MRI scans showing the cysts, which are usually hyperintense on T1 sequences and hypointense on T2 sequences with no enhancement on contrast. Asymptomatic small cysts can be followed up over time, while large cysts with ventricular obstruction need to undergo surgical resection [5].

REFERENCES

1. Zohrevandi B, Monsef Kasmaie V, Asadi P, Tajik H. Third ventricle colloid cyst as a cause of sudden drop attacks of a 13-year-old boy. *Emerg (Tehran)* 2015;3:162-4.
2. Humphries RL, Stone CK, Bowers RC. Colloid cyst: A case report and literature review of a rare but deadly condition. *J Emerg Med* 2011;40:e5-9.
3. Roberts A, Jackson A, Bangar S, Moussa M. Colloid cyst of the third ventricle. *J Am Coll Emerg Physicians Open* 2021;2:e12503.
4. Basnawi A, Alustath A. Rapid Deterioration and fatal outcomes in colloid cyst-induced obstructive hydrocephalus: A case report. *Healthcare (Basel)* 2024;12:2155.
5. Taillibert S, Le Rhun E, Chamberlain MC. Intracranial cystic lesions: A review. *Curr Neurol Neurosci Rep* 2014;14:481.

Funding: Nil; Conflicts of interest: Nil.

How to cite this article: Balagopal K, George J, Kuruvilla E, Khader AA, John J, Philip N. A rare cause of drop attacks in a young male. *Indian J Case Reports*. 2025;11(12):681-682.