

Three-dimensional debulking of eyelids in a case of pachydermoperiostosis: A case report

Sara Ahmed Elbannan¹, Ahmed Mostafa Ibrahim², Ahmed Hamdy Shawky Elzekaity³, Eman Mohamed Elsayed Emam⁴, Sarah Ahmed Hassan⁵

From ¹Assistant Lecturer, ²Specialist, ³Assistant Lecturer, Department of Ophthalmology, ⁴Professor, ⁵Lecturer, Department of Pathology, Alexandria University Faculty of Medicine, Alexandria, Egypt

ABSTRACT

Pachydermoperiostosis (PDP) is a rare genetic disorder marked by skin thickening, digital clubbing, and periostitis. We present the case of a 53-year-old male with a 20-year history of progressive skeletal changes who developed severe eyelid hypertrophy and ptosis, leading to visual obstruction and cosmetic concerns. Diagnosis was confirmed through clinical findings, imaging, and histopathology. The patient underwent staged surgical correction, including horizontal debulking and levator plication for the upper eyelids, and wedge resections for the lower eyelids. Post-operative results showed a significant reduction in eyelid bulk, improved visual axis, and enhanced facial appearance. Histopathology of the excised tissue revealed sebaceous gland hyperplasia, mucin deposition, and foreign body granulomas, consistent with PDP. This case demonstrates that individualized surgical intervention can effectively manage the functional and aesthetic complications of eyelid involvement in PDP.

Key words: Digital clubbing, Ectropion, Eyelid hypertrophy, Pachydermoperiostosis, Ptosis

Pachydermoperiostosis (PDP) is a rare, autosomal dominant disorder characterized by a triad of clinical manifestations: Pachydermia, digital clubbing, and periostitis. First described by the French physician Gérard-Léonard Trousseau in the 19th century [1]. The pathophysiology of PDP is not yet fully understood, but it is believed to involve complex interactions between genetic, environmental, and cellular factors. Recent advancements in genetic research have identified mutations in the histone deacetylase 8 gene as a common cause of the condition, although the full spectrum of genetic variations remains under investigation [2]. Furthermore, PDP was reported to result from increased prostaglandin E2 levels due to defective prostaglandin degradation, either due to a mutation in the solute carrier organic anion transporter family, member 2A1 gene coding for a prostaglandin transmembrane transporter or the hydroxyprostaglandin dehydrogenase gene responsible for intracellular degradation [3]. High levels of PGE2 can result in prolonged vasodilation, which may be the cause of digital clubbing [4]. Clinically, PDP can present in both familial and sporadic forms, with symptoms often appearing in late childhood or early adulthood [5]. The cutaneous manifestations, including

thickened skin and scalp lesions, along with joint pain and digital deformities, can significantly impact the quality of life for affected individuals. In addition, the condition's progression can lead to severe skeletal changes and associated comorbidities [6].

To the best of our knowledge, our patient is the third Egyptian patient with PDP reported in the literature [7,8].

CASE PRESENTATION

A 53-year-old male patient presented with a primary complaint of severe ptosis that obscured his visual axis. The onset of his condition began approximately 20 years prior, initially manifesting as cystic swellings over the joints of the wrists and knees. Over time, he experienced progressive enlargement of his hands and feet and significant eyelid hypertrophy and the resulting ptosis.

On physical examination, his vital signs showed a heart rate of 85 beats/min with normal blood pressure of 120/70 mmHg. He had a clear chest with a respiratory rate of 17 breaths/min and a body temperature of 37° C. The rest of the physical examination showed increased corrugation of the forehead. The skin on the forehead appeared thickened and indurated, while there was significant enlargement of the fingers and toes, characterized by distal clubbing and paronychia. The

Access this article online

Received - 08 September 2025
Initial Review - 22 September 2025
Accepted - 07 November 2025

Quick Response code



DOI: 10.32677/ijcr.v11i12.7847

Correspondence to: Sara Ahmed Elbannan, 15 Mohamed Masoud Street, Wabour Elmyah, Alexandria, Egypt. E-mail: saraelbannan@gmail.com

© 2025 Creative Commons Attribution-NonCommercial 4.0 International License (CC BY-NC-ND 4.0).

patient also presented with palmoplantar keratoderma, marked by thickened skin on the palms and soles (Fig. 1). Despite these signs, he had a normal gait and a full range of joint movements. On ophthalmic examination, the patient exhibited both upper and lower eyelid hypertrophy with severe ptosis that completely covered the visual axis. In addition, he demonstrated notable lower lid ectropion with subsequent epiphora, yet no signs of corneal exposure were detected.

Cardiac echo, abdominal and pelvic ultrasound, and chest X-ray were normal. Imaging studies of the hands and feet showed onychodystrophy and periosteal reaction along the distal metadiaphyses of the long bones of the wrists, diffuse uniform synovial hypertrophy of grade I-II, mild enthesitis at the insertion of the flexor tendons, and preserved joint spaces with no evidence of erosions, deformities, or periarticular osteopenia. These findings were consistent with PDP, a rare condition characterized by a combination of cutaneous, skeletal, and ocular manifestations.

Given the severity of the ptosis and the hypertrophy of both the upper and lower eyelids, we planned the

surgical intervention to correct the eyelid deformities. The initial phase involved performing surgical correction on one eyelid to evaluate the effectiveness of the chosen technique, followed by subsequent surgeries on the remaining eyelids based on the outcomes observed.

For the surgical management of the ptosis and lower lid ectropion, we employed the following techniques. For the upper eyelids, horizontal T-shaped full-thickness resection with levator muscle plication was done. A wedge-shaped resection was performed on the lateral aspect of the upper eyelid to reduce the eyelid mass and correct the ptosis (Fig. 2a). The levator palpebrae superioris muscle was dissected to gain access to the tarsus (Fig. 2b). A horizontal debulking of the tarsus was conducted, removing a full-thickness segment from the middle of the tarsal plate while preserving the superior and inferior portions to maintain the natural eyelid arcades (Fig. 2c and d). The remaining superior and inferior edges of the tarsus were sutured together. The levator muscle was then plicated and sutured to the anterior aspect of the tarsus to correct the ptosis and support the new lid position and the lateral aspect

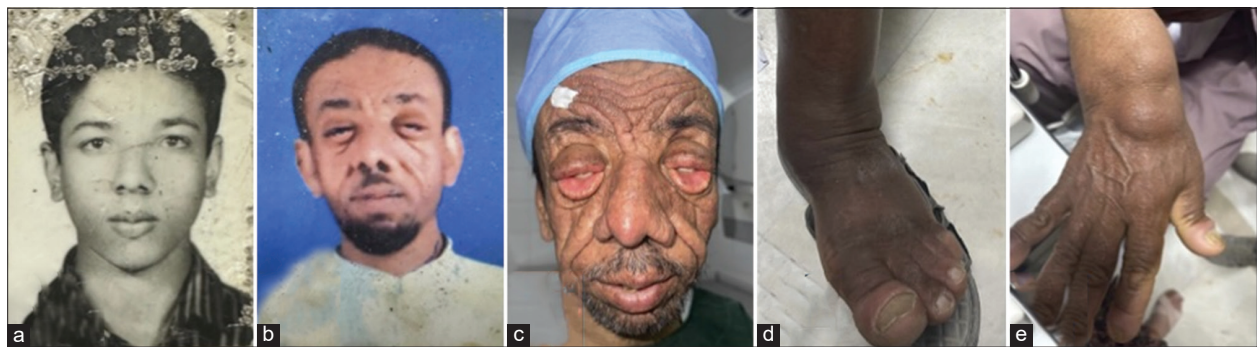

Figure 1: (a-c) The progression of the facial morphological features over 20 years with severe ptosis obscuring the visual axis and lower lid ectropion in Fig 1c; (d and e) hands and feet changes (clubbing, onychodystrophy, periosteal reaction, and synovial hypertrophy)

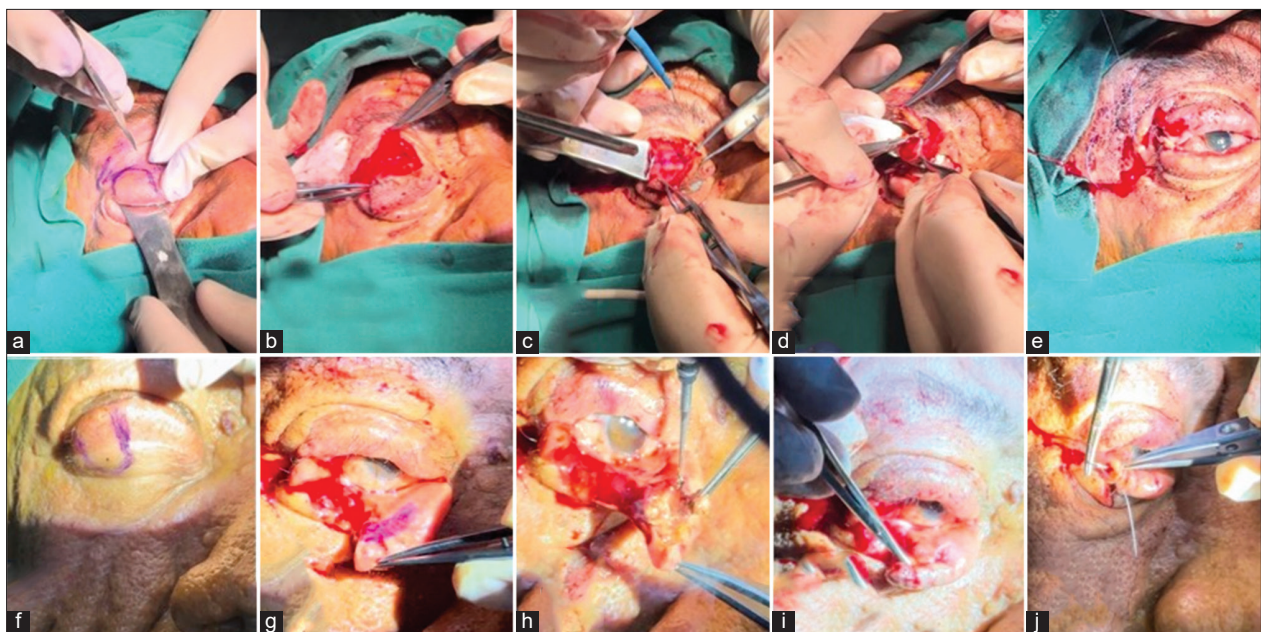


Figure 2: (a-e) Steps of upper lid surgery: (a) intraoperative marking of the resected part of upper lid, (b) dissection of levator muscle, (c and d) steps of tarsus debulking, (e) closure of lid upper lid margin in layers. (f-j) showing steps of lower lid surgery: (f) intraoperative marking of the resected part of lower lid, (g and h) steps of tarsus debulking, (i and j) closure of lid lower lid margin in layers.

of the lid was sutured in layers (Fig. 2e). For the lower eyelids, horizontal T-shaped full-thickness resection was done. A wedge-shaped resection was performed on the lateral aspect of the lower eyelid to reduce the eyelid mass (Fig. 2f). A horizontal debulking of the tarsus was conducted, removing a full-thickness segment from the middle of the tarsal plate while preserving the superior and inferior portions to maintain the natural eyelid arcades (Fig. 2g and h]. The excised tissue was then evaluated, and the lower lid was re-approximated (Fig. 2i) and the lateral aspect of the lid was sutured in layers (Fig. 2j).

Sections through the excised eyelid tissues revealed unremarkable epidermis: The dermis showed evident sebaceous gland hyperplasia with preserved lobular configuration (Fig. 3a). A dense inflammatory reaction formed of lymphocytes, plasma cells, and histiocytes was noted (Fig. 3c). A foreign body granulomatous reaction was also detected, formed of multinucleated foreign body type giant cells, lymphocytes, and histiocytes, some of which were seen around proteinaceous material (Fig. 3b and d). Cystically, dilated pilosebaceous units were also noted. Dilated infoldings of the conjunctival epithelium were seen; their lumen was filled with inspissated secretions forming corpora amylacea-like concretions (Fig. 3d). The

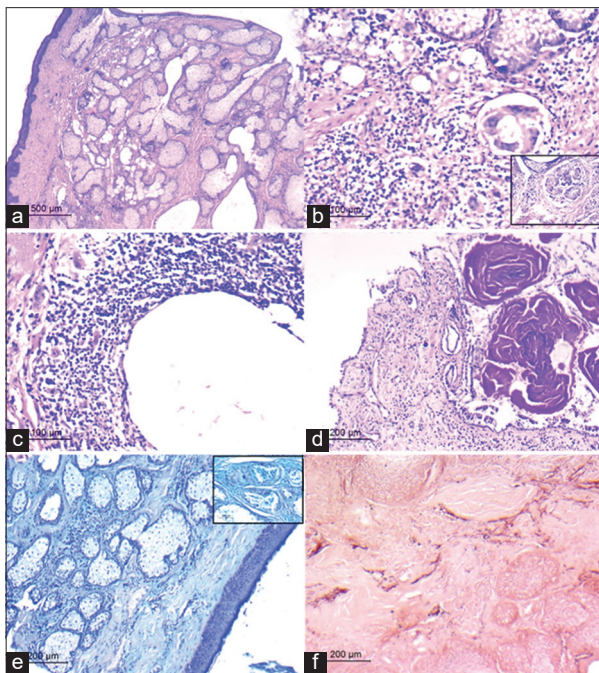


Figure 3: Representative histopathologic sections from the eyelid tissues. (a): Evident sebaceous gland hyperplasia was noted. (b and c): A dense mixed inflammatory infiltrate formed of lymphocytes, histiocytes, plasma cells, and polymorphonuclear leukocytes was seen as well as aggregates of multinucleated foreign body type giant cells (Figure 3b-inset). (d): Infoldings of the conjunctival epithelium filled with concentric secretions. (e): Increased dermal ground substance highlighted by Alcian blue stain. Foamy macrophages and multinucleated giant cells also showed Alcian blue-positive material (3e-inset). (f): Focal elastic fiber degeneration was highlighted by Orcein stain. (Figure 3a: Hematoxylin and Eosin [H and E] stain $\times 500$. Figures 3b, 3b-inset and 3c: H and E stain $\times 200$, Figure 3d: H and E $\times 100$, Figures 3e: Alcian blue stain, $\times 100$, 3e-inset, Alcian blue stain, $\times 200$ and 3f: Orcein stain, $\times 100$)

inflammation was centered around the hair follicles in areas with focal polymorphonuclear leukocyte infiltrate extending to the follicular epithelium. Increased dermal collagen was noted with dermal edema and increased ground substance. Alcian blue showed a diffuse blue staining pattern, highlighting dermal edema and the increased ground substance. Foamy macrophages and multinucleated giant cells also showed Alcian blue-positive material (Fig. 3e-inset). Degeneration of elastic fibers was focally seen and was highlighted by Orcein stain (Fig. 3f).

Following the initial surgical intervention to correct the right upper lid, there was a notable enhancement in the visual axis, which led to significant patient satisfaction. Two weeks after the initial surgery, a second procedure was performed to correct the remaining three lids. The patient has expressed a high level of satisfaction with the outcomes of both surgeries, reporting significant improvement in both functional and cosmetic aspects (Table 1) (Fig. 4). The patient was then referred to the orthopedic for subsequent management of the skeletal deformities.

DISCUSSION

This case report highlights the challenges in diagnosing and managing PDP, a rare condition characterized by a triad of pachydermia, digital clubbing, and periostitis. The patient's presentation with progressive cystic swellings in the joints, along with the development of severe eyelid hypertrophy and ptosis, aligns with the hallmark features of PDP. The condition demonstrates clinical overlap with several other disorders, including endocrine causes such as acromegaly, thyroid acropathy, and chronic hypothyroidism. It may also mimic secondary hypertrophic osteoarthropathy, which can arise from a variety of systemic conditions, most notably pulmonary diseases (e.g., cystic fibrosis, bronchiectasis, lung carcinoma), cardiac abnormalities (particularly cyanotic congenital heart disease), and gastrointestinal disorders (such as primary biliary cirrhosis and inflammatory bowel disease) that complicate diagnosis. Furthermore, this condition was reported in certain malignancies such as Hodgkin's lymphoma and chronic myeloid leukemia. In this secondary form, the cutaneous manifestations are often less frequent [7]. Other mimickers are certain types of psoriatic arthritis, such as psoriatic onychopachydermo-periostitis, which is often limited to the extremities and rheumatoid arthritis, which lacks the associated pachyderma and can be ruled out by the appropriate laboratory tests [9].

The comprehensive diagnostic workup, including normal cardiac, abdominal, and chest imaging, alongside the specific findings from hand and foot imaging, helped confirm the diagnosis of PDP, thus highlighting the importance of the multidisciplinary approach to such complex cases with potential multisystem involvement. The management plan was put forth to address all the

Table 1: Pre-operative and post-operative eyelid dimensions

Eyelid involved	Vertical height		Transverse length		Lid margin thickness	
	Pre-operative	Post-operative	Pre-operative	Post-operative	Pre-operative	Post-operative
Right upper lid	40 mm	20 mm	59 mm	40 mm	9 mm	5 mm
Left upper lid	37 mm	20 mm	55 mm	40 mm	9 mm	7 mm
Right lower lid	35 mm	20 mm	50 mm	35 mm	6 mm	4 mm
Left lower lid	32 mm	20 mm	48 mm	35 mm	6 mm	6 mm

Vertical Height: The height of the eyelid from the eyelid margin to the superior or inferior orbital margins, Transverse Length: The horizontal measurement across the eyelid, Lid Margin Thickness: The thickness of the eyelid margin at the central point

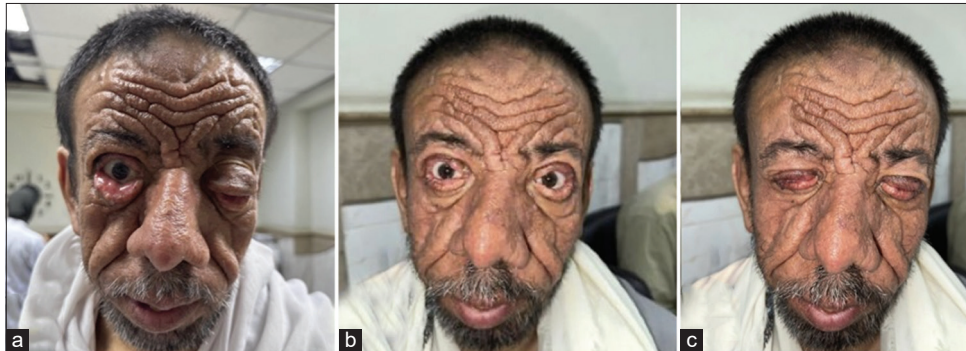


Figure 4: (a) After the first surgery showing the corrected ptosis in the right eye with exposure of the visual axis, (b and c): After the second surgery showing corrected ptosis and ectropion with no corneal exposure and with good lid apposition

patients' complaints, namely obscuration of vision (due to ptosis), discomfort and watering (due to lower lid ectropion), and cosmetic disfigurement. Given the rarity of the condition and the potential variability of the patient response to surgery, a staged approach was chosen to evaluate the outcome of the surgical procedure on one eyelid before subsequent application to the remaining 3 eyelids. Debulking of the tarsus was the procedure of choice to correct the element of mechanical ptosis, while levator muscle plication was resorted to augment the repair. The shortening of the lower eyelid (wedge-resection from the lateral aspect of the tarsus) was a crucial step to correct the lower eyelid ectropion (together with the debulking of the lower eyelid). The correction of both issues with the associated skin debulking markedly alleviated the patient's cosmetic complaint. The reduction in lid dimensions and the absence of corneal exposure post-operatively indicate that the interventions effectively addressed the primary concerns of ptosis and visual obstruction.

Histopathological examination of the excised eyelid tissues in the current case revealed findings compatible with those previously reported in the literature [7]. Epidermal acanthosis, hyperkeratosis, and parakeratosis were also among the reported histopathological changes in the literature [10,11], however, these findings were not detected in the current case.

The triad of mucin deposition, dermal edema, and elastic fiber degeneration, which was observed in the present case, was reported to occur at an early stage of the disease and could be considered diagnostic of this condition [12]. The pathogenesis of PDP is still considered a matter of debate. Whereas some authors reported increased fibroblast proliferation [13], another study contradicted this view and stated that levels of

sulfated glycosaminoglycans and proteoglycans were markedly elevated. In keeping with these findings, Alcian blue-positive material and tenascin were also observed in the connective tissue [14].

CONCLUSION

This case highlights the diagnostic and therapeutic complexities associated with PDP, demonstrating the effectiveness of a tailored surgical approach in managing severe ptosis and improving patient quality of life. The integration of detailed histopathological and clinical findings contributes to a deeper understanding of this rare condition and informs future clinical practices and research.

REFERENCES

- Sandoval AR, Robles BJ, Llanos JC, Porres S, Dardón JD, Harrison RM. Cutis verticis gyrata as a clinical manifestation of Touraine-Solente-Gole' syndrome (pachydermoperiostosis). *BMJ Case Rep* 2013;2013:bcr2013010047.
- Hernandez M, Abella M, Rojas A. Genetic aspects of pachydermoperiostosis: A review of the literature. *Genet Res* 2018;100:1-3.
- Uppal S, Diggle CP, Carr IM, Fishwick CW, Ahmed M, Ibrahim GH, *et al.* Mutations in 15-hydroxyprostaglandin dehydrogenase cause primary hypertrophic osteoarthropathy. *Nat Genet* 2008;40:789-93.
- Kim HJ, Koo KY, Shin DY, Kim DY, Lee JS, Lee MG. Complete form of pachydermoperiostosis with *SLCO2A1* gene mutation in a Korean family. *J Dermatol* 2015;42:655-7.
- Thiele GE, Reyhan I. Case report: Complicated presentation eventually explained by rare syndrome. *Rheumatologist* 2024;18. Available from: <https://www.the-rheumatologist.org/article/case-report-complicated-presentation-eventually-explained-by-rare-syndrome/>
- Gong J, Wei Q, Zhang X. Pachydermoperiostosis and associated comorbidities. *Bone Joint J* 2017;99-B:1074-81.
- Salah BI, Husari KI, Hassounch A, Al-Ali Z, Rawashdeh B. Complete primary pachydermoperiostosis: A case report from

- Jordan and review of literature. Clin Case Rep 2019;7:346-52.
8. Al Emadi S, Mehdi S. Pachydermoperiostosis: Report of two cases. Qatar Med J 2006;15:72-4.
 9. Auger M, Stavrianeas N. Pachydermoperiostosis. In: Orphanet Encyclopedia. United States: Wiley; 2004.
 10. Gómez Rodríguez N, Ibáñez Ruán J, González Pérez M. Primary hypertrophic osteoarthropathy (pachydermoperiostosis). Report of two familial cases and literature review. Reumatol Clin 2009;5:259-63.
 11. Abdullah NR, Jason WL, Nasruddin AB. Pachydermoperiostosis: A rare mimicker of acromegaly. Endocrinol Diabetes Metab Case Rep 2017;2017:17-0029.
 12. Tanese K, Niizeki H, Seki A, Otsuka A, Kabashima K, Kosaki K, *et al.* Pathological characterization of pachydermia in pachydermoperiostosis. J Dermatol 2015;42:710-4.
 13. Castori M, Sinibaldi L, Mingarelli R, Lachman RS, Rimoin DL, Dallapiccola B. Pachydermoperiostosis: An update. Clin Genet 2005;68:477-86.
 14. Abdul Mubing MF, Abdul Rahman R, Badrin S, Ibrahim H. Complete pachydermoperiostosis: A case report. Electron J Gen Med 2024;21:em554.

Funding: Nil; Conflicts of interest: Nil.

How to cite this article: Elbannan SA, Ibrahim AM, Elzekaity AH, Emam EM, Hassan SA. Three-dimensional debulking of eyelids in a case of pachydermoperiostosis: A case report. Indian J Case Reports. 2025;11(12):629-633.