

Unraveling isolated polycystic pancreatic disease: A clinical rarity and its review in literature

Namit Gupta¹, Ashok Jhajharia², Vidhyadhar Singh Nitar², Anirudh Gupta¹, Rupesh Kumar Pokharna², Prachis Ashdhir²

From ¹Senior Resident, ²Professor, Department of Gastroenterology, Sawai Man Singh Medical College and Hospital, Jaipur, Rajasthan, India

ABSTRACT

Pancreatic cysts are common, with pseudocysts being the most frequent. Polycystic pancreatic disease usually coexists with cysts in other solid organs, but isolated involvement of the pancreas is rare. This report presents a case of a 40-year-old female who presented with vague abdominal discomfort and pain with no history of pancreatitis or trauma. Radiological imaging showed multiple variable-sized thin-walled pancreatic cysts with no cystic lesions in the liver, spleen, kidneys, or brain. The patient was diagnosed with isolated polycystic disease of the pancreas and is on conservative management with regular follow-up. In summary, idiopathic isolated macro-polycystic disease of the pancreas is a rare condition that is usually asymptomatic with a benign outcome and is primarily diagnosed through imaging techniques, with magnetic resonance imaging being the most accurate. Further data and experience are needed to develop standardized treatment protocols in case of significant symptoms.

Key words: Abdominal pain, Pancreatic cysts, Polycystic pancreatic disease

Pancreatic cysts are commonly encountered in clinical practice; imaging studies have shown a prevalence in the range of 2–15%; however, autopsy data suggest a prevalence as high as 50% [1,2]. Pancreatic cysts can be classified into several types: Congenital, inflammatory, and neoplastic; among these, inflammatory cysts, particularly pseudocysts, are the most common, while congenital pancreatic cysts are the rarest [3]. Solitary congenital pancreatic cysts are usually isolated, whereas congenital polycystic pancreatic disease is typically associated with cysts in other solid organs such as the kidneys, liver, brain, and spleen; however, isolated polycystic involvement of the pancreas is extremely rare. This case highlights the clinical presentation and identification of this uncommon entity, as well as explores potential management strategies and follow-up protocol [4].

CASE REPORT

A 40-year-old female presented to our gastroenterology department with vague abdominal discomfort and dull aching abdominal pain in the epigastric region for the past 4 months. The pain was non-radiating, mild to moderate

in intensity, and was relieved with oral analgesics. There was no associated vomiting, diarrhea, steatorrhea, fever, weight loss, or loss of appetite. The patient reported no history suggestive of acute pancreatitis, trauma, or significant past or family history.

On examination, the patient had stable vital signs and a normal general physical assessment with no significant abnormality. Systemic examination revealed a soft abdomen with no tenderness, rigidity, or palpable masses.

Routine laboratory investigations, including a hemogram, liver function tests, serum amylase, lipase levels, glycosylated hemoglobin levels, tumor markers (carcinoembryonic antigen and cancer antigen 19-9), and hydatid serology, were all within normal limits. A whole abdomen ultrasound revealed multiple hypoechoic cysts in the pancreas. Doppler ultrasound revealed multiple well-defined lesions with no color flow or vascularity (Fig. 1). A contrast-enhanced computed tomography (CECT) scan showed multiple variable-sized hypodense cysts throughout the head, body, and tail of the pancreas, the largest cyst measuring 34 × 30 mm, with no evidence of pancreatic or peripancreatic inflammation, solid components, or calcifications (Fig. 2). Magnetic resonance cholangiopancreatography showed multiple thin-walled cystic lesions, and the cysts were not

Access this article online

Received - 17 August 2025
Initial Review - 15 September 2025
Accepted - 24 October 2025

Quick Response code



DOI: 10.32677/ijcr.v11i12.7835

Correspondence to: Prachis Ashdhir, Department of Gastroenterology, Sawai Man Singh Medical College, Jaipur, Rajasthan, India. E-mail: pa894@yahoo.co.in

© 2025 Creative Commons Attribution-NonCommercial 4.0 International License (CC BY-NC-ND 4.0).

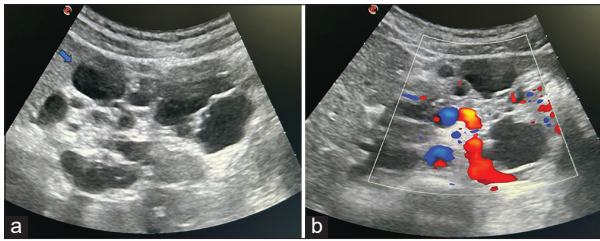


Figure 1: (a) Ultrasonography W/A showing multiple hypoechoic cysts in the pancreas (arrow), (b) Doppler ultrasound revealed multiple well-defined lesions with no color flow or vascularity

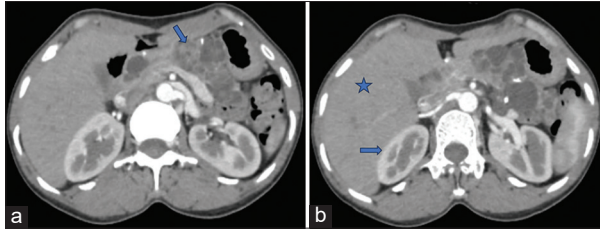


Figure 2: (a) Contrast-enhanced computed tomography whole abdomen showing multiple hypodense variable-sized cysts throughout the head, body, neck, and tail of the pancreas (arrow), (b) Normal liver (star) and kidneys (arrow) parenchyma with no cystic lesion

communicating with the pancreatic ducts (Fig. 3). There were no cystic lesions seen in the liver, spleen, or kidneys on any radiological imaging. Given the possibility of Von Hippel–Lindau (VHL) syndrome, brain imaging (non-contrast CT head) was performed and showed no cysts in the brain. Endoscopic ultrasound also showed multiple cysts in the pancreas without any flow on color Doppler (Fig. 4). Genetic testing for a mutation in the VHL tumor suppressor gene on the short arm of chromosome 3 was also negative.

The patient was diagnosed with isolated multiple pancreatic cysts, and has mild abdominal discomfort and intermittent mild intensity upper abdominal pain for which she is currently receiving conservative treatment with antispasmodic agents (drotaverine plus mefenamic acid) as per requirement. The patient has been on regular follow-up for the past 8 months with periodic whole abdominal ultrasound and color Doppler studies. During this period, a notable improvement in symptoms has been noted, with no appreciable changes in the size or characteristics of the pancreatic cysts.

DISCUSSION

The incidence of pancreatic cysts has increased in the past few decades, which may be due to the increasing use of CT or magnetic resonance imaging (MRI) scans, and the increasing mean age of individuals [5]. There are over 20 types of epithelial and non-epithelial pancreatic cysts; among these, the two most prevalent benign lesions, pseudocysts and serous cystadenomas, account for approximately 75% of all pancreatic cyst cases. Serous cystadenomas are well-circumscribed pancreatic tumors with numerous tiny cysts and delicate septa, giving a honeycomb appearance on cross-section [6].

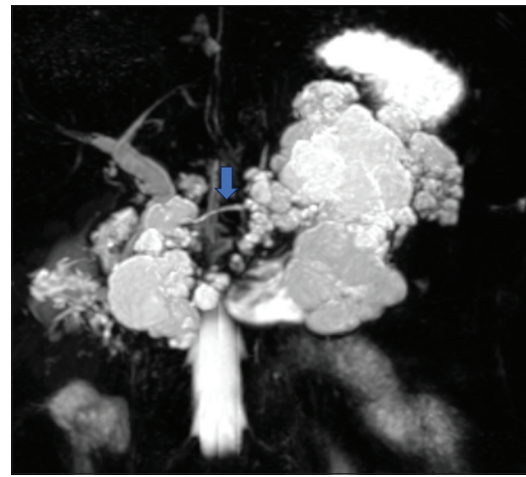


Figure 3: Magnetic resonance cholangiopancreatography abdomen showing multiple variable-sized hyperintense thin-walled in pancreas with no communication with pancreatic ducts (arrow showing pancreatic duct)

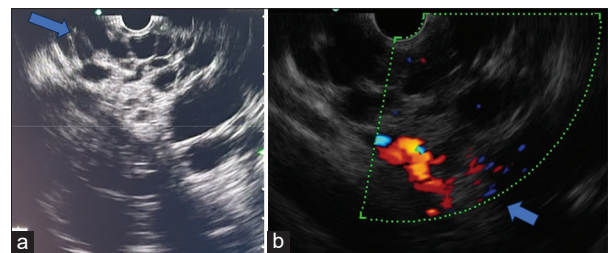


Figure 4: (a) Endoscopic ultrasound showing multiple variable-sized cysts in pancreas (arrow), (b) On color Doppler there is no flow in cysts (arrow)

Pancreatic cystic lesions may also be classified as congenital or acquired, such as neoplastic and inflammatory [3]. Congenital pancreatic cysts are also known as true pancreatic cysts as they have an epithelial lining on their inner surface, which distinguishes them from pseudocysts that lack this lining; therefore, histopathological examination is essential to differentiate true cysts from other cystic lesions. Congenital pancreatic cysts can be solitary or multiple; solitary pancreatic cysts are typically present isolated, whereas multiple pancreatic cysts often have cysts in other solid organs also, these include syndromes such as autosomal dominant polycystic kidney disease (ADPKD), Beckwith–Wiedemann syndrome, and VHL disease [4,7]. An isolated form of the polycystic pancreatic disease is seldom observed, with only limited case reports available in the clinical literature [8,9].

Another entity, polycystic disease of the pancreas, which is also known as pancreatic polycystosis or dysontogenetic cysts, primarily results from abnormal development of the pancreatic ductal system, often due to ciliopathy. A deficiency in hepatocyte nuclear factor VI and a gain-of-function mutation in forkhead box protein have been linked to an increased risk of developing pancreatic cysts [10]. These cysts are characterized by the absence of primary cilia, similar to those seen in polycystic kidney disease and commonly associated with ADPKD [11].

Isolated polycystic disease of the pancreas is generally considered benign and carries a low risk

of malignant transformation. Polycystic pancreatic disease is often asymptomatic and may be incidentally discovered on imaging or autopsy. It may present with non-specific symptoms such as abdominal discomfort or pain, steatorrhea, and occasionally with episodes of acute pancreatitis; most cases reported in the literature presented with non-specific abdominal symptoms [8,9,12]. However, Katsinelos *et al.* described a case where the patient initially presented with steatorrhea, leading to the eventual diagnosis of isolated polycystic disease of the pancreas [13].

The diagnosis of isolated pancreatic polycystic disease involves a range of imaging techniques, from basic modalities such as abdominal ultrasound and Doppler studies to more advanced imaging such as CECT and MRI scans. Doppler ultrasound usually reveals multiple well-defined, anechoic lesions with no color flow or vascularity, indicative of simple fluid-filled cysts. On CT scans, these cysts are characterized by macro-cystic, multilocular lesions throughout the pancreas, causing pancreatic enlargement [14]. MRI imaging shows simple cysts that are hypointense on T1-weighted images and hyperintense on T2-weighted images [8]. Both Ozturk *et al.* and Dhar *et al.* emphasized the pivotal role of MRI in diagnosing isolated polycystic pancreatic disease, highlighting its advantages over other imaging modalities [7,9].

The management of polycystic pancreatic disease is based on the patient's symptoms. Asymptomatic cases with diffuse pancreatic involvement can generally be monitored with regular follow-up and do not require therapeutic intervention. In contrast, symptomatic cases may require treatment, such as laparoscopic fenestration, and for more severe symptoms, segmental pancreatectomy may be necessary to remove the dominant cyst. Fenestration is usually performed for macrocystic forms, while segmental pancreatectomy or surgical resection is reserved for microcystic lesions or cases with uncertain characteristics [14,15]. The screening and follow-up protocol should align with established pancreatic cyst guidelines, focusing on risk-based imaging and the early detection of high-risk features.

CONCLUSION

This is a rare case of idiopathic isolated macro-polycystic disease of the pancreas. The clinical presentation of such a condition can vary, with most patients having mild symptoms, and the nature of this condition is usually benign. Diagnosis is primarily based on imaging techniques such as ultrasonography, Doppler studies, CECT, and MRI, with MRI being the most accurate. Management is largely symptom-driven and may involve either medical or surgical approaches. Further data and experience are needed to establish comprehensive and individualized management protocols.

AUTHOR CONTRIBUTIONS

N.G., and P.A. have Substantial contributions to the conception or design of the work; or the acquisition, analysis, or interpretation of data for the work; and N.G., A.J., V.N., and P.A. had drafted the work or reviewed it critically for important intellectual content; and R.P. and P.A. have given final approval of the version to be published; and agreement to be accountable for all aspects of the work in ensuring that questions related to the accuracy or integrity of any part of the work are appropriately investigated and resolved.

REFERENCES

1. Romutis S, Brand R. Burden of new pancreatic cyst diagnosis. *Gastrointest Endosc Clin N Am* 2023;33:487-95.
2. Kromrey ML, Bülow R, Hübner J, Paperlein C, Lerch MM, Ittermann T, *et al.* Prospective study on the incidence, prevalence and 5-year pancreatic-related mortality of pancreatic cysts in a population-based study. *Gut* 2018;67:138-45.
3. Shahid M, Javed Z, Usman M, Iltaf S. True congenital pancreatic cyst: A rare entity. *Cureus* 2018;10:e3318.
4. Kucera JN, Kucera S, Perrin SD, Caracciolo JT, Schmulewitz N, Kedar RP. Cystic lesions of the pancreas: Radiologic-endosonographic correlation. *Radiographics* 2012;32:E283-301.
5. Schweber AB, Agarunov E, Brooks C, Hur C, Gonda TA. Prevalence, incidence, and risk of progression of asymptomatic pancreatic cysts in large sample real-world data. *Pancreas* 2021;50:1287-92.
6. Nagtegaal ID, Odze RD, Klimstra D, Paradis V, Rugge M, Schirmacher P, *et al.* The 2019 WHO classification of tumours of the digestive system. *Histopathology* 2020;76:182-8.
7. Ozturk M, Bekci T, Danaci M, Ayyildiz T. Isolated polycystic pancreatic disease. *Am J Diagn Imaging* 2018;4:24-5.
8. Jain VK, Jain J, Singh R, Gupta S. Isolated polycystic disease of pancreas. *Indian J Gastroenterol* 2016;35:250-1.
9. Dhar DA, Suchi T, Garg S, Dixit VK. A rare isolated polycystic pancreatic disease. Radiation free diagnostic protocol in selected cases. *Indian J Endocrinol Metab* 2012;16:1054-6.
10. Kikuchi O, Kobayashi M, Amano K, Sasaki T, Kitazumi T, Kim HJ, *et al.* FoxO1 gain of function in the pancreas causes glucose intolerance, polycystic pancreas, and islet hypervascularization. *PLoS One* 2012;7:e32249.
11. Sonavane AD, Amarapurkar DN, Amarapurkar AD. Polycystic pancreas. *ACG Case Rep J* 2016;3:199-201.
12. Patel VP, Vinaykumar PT, Parmar SS. Isolated polycystic disease of the pancreas. *Int J Adv Res* 2022;10:396-8.
13. Katsinelos P, Lazaraki G, Anastasiadis S. Isolated polycystic pancreatic disease: A very rare cause of pancreatic insufficiency. *Clin Gastroenterol Hepatol* 2018;16:e121.
14. Hamidi H. Polycystic Disease of Pancreas. Case study; 2023. Available from: <https://radiopaedia.org> [Last accessed on 2025 Jun 27].
15. Martinez-Perez A, Alberola-Soler A, Domingo-del Pozo C, Pemartin-Comella B, Martinez-Lopez E, Vazquez-Tarragon A. Laparoscopic surgery and polycystic liver disease: Clinicopathological features and new trends in management. *J Minim Access Surg* 2016;12:265-70.

Funding: Nil; Conflicts of interest: Nil.

How to cite this article: Gupta N, Jhajharia A, Nitar VS, Gupta A, Pokharna RK, Ashdhir P. Unraveling isolated polycystic pancreatic disease: A clinical rarity and its review in literature. *Indian J Case Reports*. 2025;11(12):614-616.