

Anesthesia for combined off-pump coronary artery bypass grafting with radical nephrectomy and inferior vena cava tumor excision extending to the right atrium: A case report

Kuzhithattil Aniyar Koshy¹, Kizakke K Pradeep²

From ¹Consultant and Head, Department of Cardiac Anesthesia, ²Consultant and Head, Department of Cardiac Surgery, Lourdes Hospital, Kochi, Kerala, India

ABSTRACT

This case report describes the successful anesthesia management of a 60-year-old male with renal cell carcinoma extending into the inferior vena cava (IVC) and right atrium (RA). Utilizing transesophageal echocardiography for real-time monitoring and cardiopulmonary bypass with deep hypothermia and selective antegrade cerebral perfusion, a multidisciplinary team achieved complete tumor resection. The patient's complex medical history included type 2 diabetes, hypertension, and coronary artery disease, necessitating concurrent coronary artery bypass grafting (CABG). The surgical approach included IVC and RA tumor excision and careful perioperative management to address significant blood loss, potential thromboembolism, and post-operative complications such as atrial fibrillation, low cardiac output, and hepatic dysfunction. This case underscores the importance of advanced intraoperative monitoring and a collaborative, multidisciplinary approach in managing concomitant CABG and renal cell carcinoma with intracardiac extension, achieving a successful outcome despite the high complexity and risk.

Key words: Cardiopulmonary bypass, Coronary artery bypass grafting, Level IV inferior vena cava tumor, Renal cell carcinoma, Transesophageal echocardiography


Renal cell carcinoma (RCC) tumor thrombus extending into the inferior vena cava (IVC) and reaching the right atrium (RA) occurs in only 0.3–1.0% of cases [1]. Surgical resection is the only curative option. The relationship of the IVC tumor thrombus to the liver, hepatic veins, diaphragm, and RA determines its staging (Fig. 1) [2]. The rationale for reporting this case lies in its rarity and complexity, involving the simultaneous management of RCC with intracardiac extension and coronary artery bypass grafting (CABG), requiring a multidisciplinary approach, advanced intraoperative monitoring, and innovative techniques to overcome significant anesthesia challenges; to the best of our knowledge, this is the first case report of such a combined procedure from India.

CASE REPORT

A 60-year-old, 68 kg, 173 cm male, classified as American Society of Anaesthesiologists (ASA) Class II, with a history of type 2 diabetes mellitus and hypertension, presented with unexplained weight loss over the past 4 months.

Magnetic resonance imaging of the abdomen and pelvis revealed a 135 × 145 mm mass arising from the lower pole of the right kidney and extending through the renal vein, reaching the IVC and RA. Pre-operative cardiology workup indicated left main and double vessel coronary artery disease and normal left ventricular systolic function. After obtaining written informed consent, the patient was scheduled for right radical nephrectomy, IVC and RA tumor excision, and CABG.

In the operating room, along with standard ASA monitors, a radial intra-arterial catheter and a central venous catheter in the right internal jugular vein (IJV) were inserted. A pulmonary artery catheter was not inserted in view of the risk of embolization of the intracardiac tumor. Baseline hemodynamic parameters were normal. Two large-bore peripheral venous catheters were inserted for fluid resuscitation. Continuous transoesophageal echocardiography (TEE) monitoring was performed. A fluid and blood-warming system was employed. General anesthesia was induced with intravenous (IV) fentanyl (2 µg/kg IV) and propofol (2 mg/kg IV). Tracheal intubation was facilitated with IV atracurium (0.5 mg/kg), and an appropriately sized cuffed endotracheal tube was secured. Anesthesia was maintained with a balanced general anesthesia

Access this article online	
Received - 09 January 2025 Initial Review - 31 January 2025 Accepted - 11 March 2025	Quick Response code 
DOI: 10.32677/ijcr.v11i4.4996	

Correspondence to: Kuzhithattil Aniyar Koshy, Flat No 1604, Oceanus Maple, V P Marikkar Road, Vattekkunnam, Edappally, Kochi - 682024, Kerala, India. E-mail: write2koshy@gmail.com

© 2025 Creative Commons Attribution-NonCommercial 4.0 International License (CC BY-NC-ND 4.0).

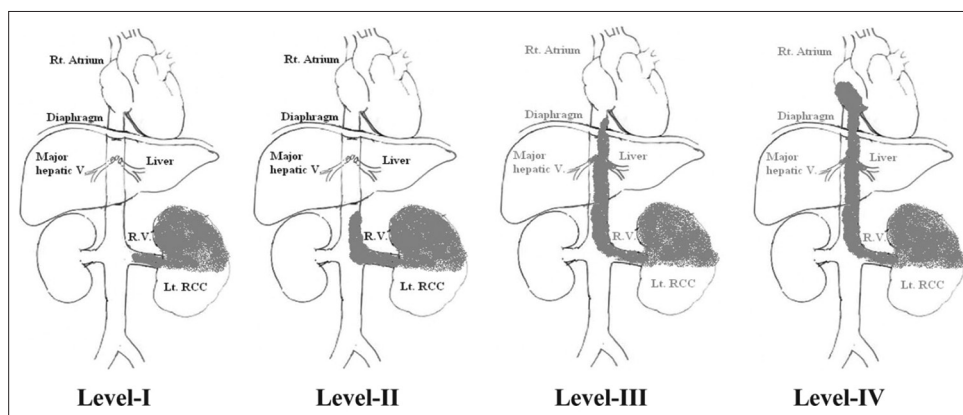


Figure 1: Staging of renal cell carcinoma [2] (Published under creative commons attribution by license. <https://creativecommons.org/licenses/by/3.0/>.)

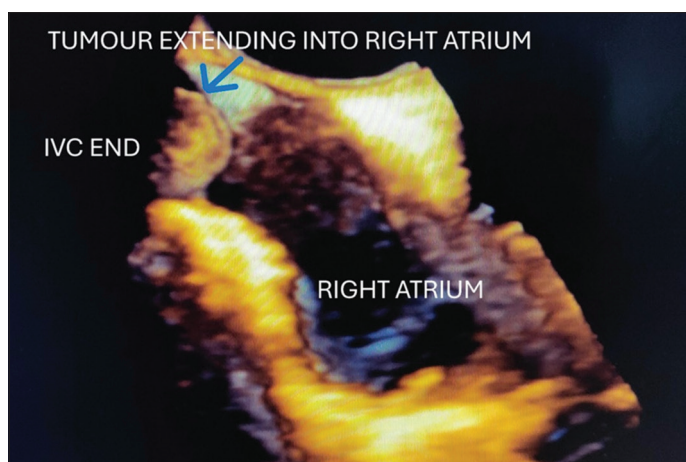


Figure 2: Live 3D transesophageal echocardiography bicaval view

technique using volatile agents (sevoflurane in oxygen and air), opioids (fentanyl infusion 1 mcg/kg/h IV), and muscle relaxants (atracurium infusion at 0.3 mg/kg/h IV).

The procedure began with a laparotomy through a chevron incision to confirm the operability of the tumor. CABG was performed using the off-pump technique with a low dose of heparin (100 IU/kg) to achieve a target-activated clotting time (ACT) of 240 s. This was to minimize cardiopulmonary bypass (CPB) time and reduce the total heparin dose administered. After reversing heparin with protamine and confirming hemostasis, the abdominal team mobilized the kidney and controlled the IVC and supra celiac aorta. The patient was re-heparinized at a dose of 300 IU/kg, achieving an ACT of 480 s. CPB was then initiated using superior vena cava and aortic cannulation. The patient was cooled to 25°C (deep hypothermia), and the abdominal aorta above the origin of the celiac artery was clamped. Selective antegrade perfusion to the upper body was initiated. The renal vein was dissected and ligated, followed by a right radical nephrectomy. The IVC was opened, and the tumor was removed while the cardiac surgeon opened the RA and removed the tumor thrombus protruding into the RA. Total CPB time was 173 min, with a cross-clamp time of 100 min and a total selective antegrade perfusion time of 46 min. Post-CPB, modified ultrafiltration (MUF) was used to remove fluids and inflammatory mediators. Mean arterial pressure was maintained

above 70 mmHg using dopamine, noradrenaline, vasopressin, and dobutamine, guided by TEE and invasive hemodynamic monitoring of vital parameters. Estimated blood loss was 3500 mL intraoperatively and 650 mL post-operatively. A total of 12 units of packed red blood cells, five units of fresh frozen plasma, and three units of platelets were empirically transfused perioperatively. Tranexamic acid (10 mg/kg IV bolus followed by 1 mg/kg/h infusion) was administered intraoperatively. The total duration of surgery was nearly 11 h.

The post-operative ventilation duration was 30 h due to delayed awakening, potentially due to the slow clearance of anesthesia drugs by the ischemic liver. Post-operative atrial fibrillation was treated with IV amiodarone and beta-blockers. Low cardiac output was managed with IV fluids and inotropes. Ileus was managed conservatively. Post-operative hepatic dysfunction, manifested by elevated liver enzymes, decreased serum albumin, and prolonged prothrombin time, normalized with supportive care. Respiratory infection, indicated by non-homogeneous opacity in the chest X-ray, responded to antibiotics. The patient was shifted to the ward on the 7th post-operative day (POD) and discharged on the 12th POD.

DISCUSSION

Surgical resection is the only curative option for RCC IVC tumors extending into the RA [3]. Major intraoperative anesthesia challenges with level 4 IVC tumor resection and concomitant CABG include long thoracic and abdominal incisions, prolonged surgery duration, significant blood loss, CPB use with deep hypothermia, and selective antegrade cerebral perfusion (SACP). Specific clinical challenges affecting morbidity and mortality include periods of lower body ischemia and reperfusion, volume resuscitation during IVC clamping, incomplete local resection, tumor embolism, and hepatic ischemic injury. Post-operative challenges include early diagnosis and management of acute kidney injury, coagulopathy, ileus, pain, respiratory and myocardial insufficiency, wound infection, and the potential need for additional surgery.

CPB support greatly improves access to the IVC and RA, while deep hypothermic circulatory arrest facilitates

a bloodless field but can contribute to cerebral injury, coagulopathy, renal, and metabolic dysfunction [4,5]. We used CPB with clamping of the abdominal aorta above the celiac artery while maintaining selective antegrade perfusion to the upper body, ensuring adequate IVC exposure and avoiding hepatic congestion. Saad and Aladawy described the beneficial effects of hypothermia when used in cardiac surgery [6]. We used deep hypothermia (25°C) for organ protection while the abdominal aorta was clamped. Fukazawa *et al.* found that patients with level IV tumors of the IVC had higher estimated blood loss and hospital stays compared to patients with level III tumors [7]. In level IV tumors, the use of systemic heparinization and CPB, deep hypothermia, and bleeding from a raw exposed retroperitoneal surface after nephrectomy can lead to higher blood transfusion. The use of antifibrinolytics, such as tranexamic acid, is recommended by the ASA task force on perioperative blood management to reduce allogenic blood transfusion in CPB patients [8]. Luciani *et al.* showed that using MUF can remove fluid overload and inflammatory mediators, reducing blood transfusion rates and early morbidity associated with CPB [9].

Real-time intraoperative monitoring with transesophageal echocardiography (TEE) enables the examination of the RA, right ventricle, and pulmonary arteries for thromboembolic pathology, biventricular function, and valvular function. Key TEE views include the mid-esophageal four-chamber, bicaval, modified transgastric, mid-esophageal right ventricular inflow-outflow, mid-esophageal aortic valve short axis, and upper esophageal aortic arch short-axis views. TEE provides critical information on tumor friability, mobility, and its relationship to hepatic veins. Martinelli *et al.* used TEE to diagnose residual tumors in the IVC post-resection [10]. Post-thrombus extraction, color Doppler on TEE confirmed laminar blood flow in the IVC, ruling out residual thrombus. We used TEE to monitor tumor thromboembolization in real-time, assess its proximal extent, verify resection, and aid in de-airing post-thrombus evacuation (Fig. 2). Oikawa *et al.* utilized TEE to position the intracaval balloon above the tumor thrombus without liver mobilization [11]. Kirkeby-Garstad *et al.* described IVC mapping to identify misplaced venous cannulae [12]. We applied this technique to visualize the IVC, eustachian valve, and main hepatic veins, assessing tumor extent. The central line in the right IJV was inserted under TEE monitoring to prevent tumor thrombus dislodgment; the left IJV route may be preferred if the tumor extends into the RA cavity.

CONCLUSION

This case highlights the successful management of RCC with tumor thrombus extending into the IVC and RA. Using TEE and CPB with deep hypothermia and SACP enabled complete tumor resection, underscoring the importance of advanced monitoring and a collaborative approach in complex RCC cases.

REFERENCES

1. Bissada NK, Yakout HH, Babanouri A, Elsalamony T, Fahmy W, Gunham M, *et al.* Long-term experience with management of renal cell carcinoma involving the inferior vena cava. *Urology* 2003;61:89-2.
2. Nouh MA, Inui M, Kakehi Y. Renal cell carcinoma with IVC thrombi; current concepts and future perspectives. *Clin Med Oncol* 2008;2:247-56.
3. Miranda M, Polido J, Fernandes M, Lopes F, Oliveira T, Lopes T, *et al.* Renal cell carcinoma with inferior vena cava thrombus: Survival and prognostic factors in surgically treated patients. *Urol Ann* 2024;16:277-83.
4. Lau C, O'Malley P, Gaudino M, Scherr DS, Girardi LN. Resection of intraabdominal tumors with cavoatrial extension using deep hypothermic circulatory arrest. *Ann Thorac Surg* 2016;102:836-42.
5. Arrowsmith JE, Conolly S, Klein AA. Deep hypothermic circulatory arrest. *Contin Educ Anaesth Crit Care Pain* 2010;10:138-42.
6. Saad H, Aladawy M. Temperature management in cardiac surgery. *Glob Cardiol Sci Pract* 2013;1:44-62.
7. Fukazawa K, Gologorsky E, Naguit K, Pretto EA Jr., Salerno TA, Arianayagam M, *et al.* Invasive renal cell carcinoma with inferior vena cava tumor thrombus: Cardiac anesthesia in liver transplant settings. *J Cardiothorac Vasc Anesth* 2014;28:640-6.
8. American Society of Anesthesiologists Task Force on Perioperative Blood Management. Practice guidelines for perioperative blood management: An updated report by the American society of anesthesiologists task force on perioperative blood management. *Anesthesiology* 2015;122:241-75.
9. Luciani GB, Menon T, Vecchi B, Auriemma S, Mazzucco A. Modified ultrafiltration reduces morbidity after adult cardiac operations: A prospective, randomized clinical trial. *Circulation* 2001;104Suppl 1:I253-9.
10. Martinelli SM, Mitchell JD, McCann RL, Podgoreanu MV, Mathew JP, Swaminathan M. Intraoperative transesophageal echocardiography diagnosis of residual tumor fragment after surgical removal of renal cell carcinoma. *Anesth Analg* 2008;106:1633-5.
11. Oikawa T, Shimazui T, Johraku A, Kihara S, Tsukamoto S, Miyana N, *et al.* Intraoperative transesophageal echocardiography for inferior vena caval tumor thrombus in renal cell carcinoma. *Int J Urol* 2004;11:189-92.
12. Kirkeby-Garstad I, Tromsdal A, Sellevold OF, Bjørngaard M, Bjella LK, Berg EM, *et al.* Guiding surgical cannulation of the inferior vena cava with transesophageal echocardiography. *Anesth Analg* 2003;96:1288-93.

Funding: Nil; Conflicts of interest: Nil.

How to cite this article: Koshy KA, Pradeep KK. Anesthesia for combined off-pump coronary artery bypass grafting with radical nephrectomy and inferior vena cava tumor excision extending to right atrium: A case report. *Indian J Case Reports*. 2025; 11(4):157-159.