

Postauricular dermoid cyst: A very rare clinicopathological entity

Shujaat Khan¹, Varun Singla², Garima Chaudhary¹, Chetna Sheoran³

From ¹Assistant Professor, ³Post-graduate Scholar, Department of Pathology, ²Prof and Head, Department of Dental, Alfalah University, Faridabad, Haryana, India

ABSTRACT

Dermoid cysts (DC) of the postauricular region are extremely rare and often present since childhood. They usually lie dormant for some time and then grow and manifest clinically because of enlargement, rupture, or sometimes extension to surrounding structures. Common differential diagnoses include epidermoid cysts, sebaceous cysts, retroauricular lymph nodes, lipomas, hemangioma, and keloids. We describe a 17-year-old male with an unusual presentation of DC in the subcutaneous tissue of the left retroauricular region. Although extremely rare, DC should be considered in the differential diagnosis of postauricular lumps. Modalities like ultrasonography, computed tomography, and fine needle aspiration cytology help narrow down the diagnosis and rule out any intracranial extension. Complete excision at an early stage is mandatory to avoid recurrence, infection, rupture, and malignant change, and for cosmetic purposes. A histopathological examination is required for confirmation and to rule out any malignant change.

Key words: Dermoid cyst, Head-and-neck cyst, Postauricular, Retroauricular

Dermoid cyst (DC) is a rare benign lesion in the head-and-neck region. It is an inclusion cyst comprising both ectodermal and mesodermal components of the germ layers. Congenital DCs are frequently located near the midline and arise from the entrapment of ectodermal elements along the lines of embryonic closure. It usually exists since birth but is usually recognized in the second or third decade of life when it grows in size, while the acquired variety is due to a penetrating trauma causing the implantation of the epidermis into the dermis [1,2]. DC may occur anywhere in the body with a prevalence of approximately 7% in the head-and-neck region, and a tendency to occur in the orbit, nose, and the region of the lateral part of the eyebrow in over 80% of the cases. Other less common sites include the neck, lip, palate, and the area of the occipital or frontal region near the midline [3]. Clinically, DC are soft, cystic, unilocular, and moveable lumps that appear as rounded and slowly growing lesions, with no specific symptoms unless they get infected [4]. Histologically, the presence of skin adnexal features such as hair follicles and sebaceous glands, as well as, the squamous epithelium, characterizes the DCs. Histopathology is required for confirmation and to rule out the possibility of malignancy. The treatment of choice for a DC is complete surgical excision to prevent a recurrence. The prognosis is excellent without further complications especially when there is no intracranial extension [2].

We report a case of DC in the left retroauricular region which was misdiagnosed as a retroauricular lymph node.

CASE REPORT

A 17-year-old male came to our dental outpatient department with a complaint of toothache in the left side of the mandible.

On oral examination, there was dental caries and associated cavity formation in his 2nd mandibular molar tooth on the left side. Extraoral examination revealed a postauricular swelling measuring 4.0 × 2.0 cm that was subcutaneous, mobile, non-tender, and mildly compressible with no local rise in temperature or overlying skin changes. After inquiring about the swelling, the patient said that the swelling had been present since early childhood but had gradually increased in size over the past 1–2 years till the present size (Fig. 1). The patient denied any additional symptoms or traumatic and inflammatory events except occasional Rhinitis and sore throat for the last 3–4 years. On general examination, the patient was well-built, and oriented with time, place, and person. Central nervous examination showed normal reflexes. Respiratory sounds were normal. Cardiovascular examination showed normal 1st and 2nd heart sounds. The rest of the physical examination and laboratory investigations were unremarkable. There were no associated hearing complaints or any other congenital anomalies. The initial picture was suggestive of an enlarged retroauricular lymph node.

Access this article online

Received - 17 September 2024
Initial Review - 01 October 2024
Accepted - 08 November 2024

Quick Response code



DOI: 10.32677/ijcr.v11i1.4824

Correspondence to: Shujaat Khan, Assistant Professor in Pathology, Al-falah School of Medical Sciences and Research Centre, Faridabad - 121004, Haryana, India. E-mail: shujapathologist123@gmail.com

© 2025 Creative Commons Attribution-NonCommercial 4.0 International License (CC BY-NC-ND 4.0).

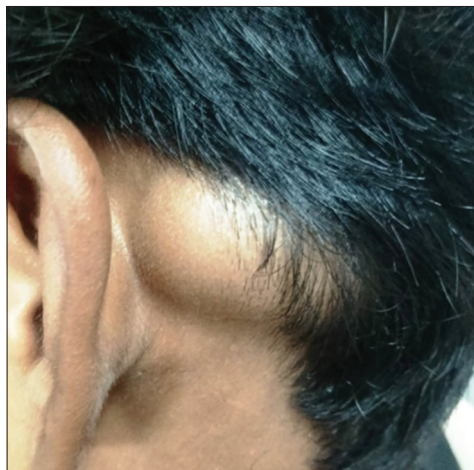

Figure 1: Pre-operative picture of the patient with postauricular swelling

On ultrasonography (USG), there was evidence of a well-defined heterogenous predominantly echogenic lesion showing internal echogenic striations measuring 42×12 mm within a subcutaneous plane in the left postauricular region. The underlying bone showed a normal cortical surface.

Fine needle aspiration cytology (FNAC) of the postauricular cyst consisted of thick greasy foul-smelling aspirate, that on microscopy showed nucleated and anucleated squamous cells, degenerated cells, keratin flakes, and mild inflammatory cell infiltrate (Fig. 2).

After narrowing down the differential diagnosis to the epidermoid cyst, DC, or trichilemmal cyst, proper consent was taken and the patient underwent complete surgical excision of the left postauricular cyst under local anesthesia for diagnostic and therapeutic indications. After the skin flap was raised, a globular, encapsulated cystic mass was seen in contact with the underlying bone.

A gross examination of the excised specimen showed a cyst measuring $4 \times 1.5 \times 1.5$ cm. The cut section was found to be filled with pultaceous material and a tuft of hair was seen within the cavity (Fig. 3). On histopathological examination (HPE), the cyst wall was lined by keratinized squamous epithelium containing hair follicles and sebaceous glands; the definitive diagnosis of DC was confirmed (Fig. 4). The patient is on follow-up and is doing well, with no evidence of recurrence.

DISCUSSION

Epidermoid, dermoid, and teratoid cysts are different types of cystic malformations. They have stratified squamous epithelium lining which is derived from the ectodermal component of the germ layer. DCs have the presence of skin adnexal structures such as hair follicles and sebaceous glands besides the squamous epithelial lining. Whereas the epidermoid cyst only has a simple squamous epithelial lining with no adnexal structures and the teratoid cyst is characterized by abnormal tissues derived from all three germinal layers such as muscles, fat, bone, and cartilage [5]. The following theories have been put forward regarding the origin

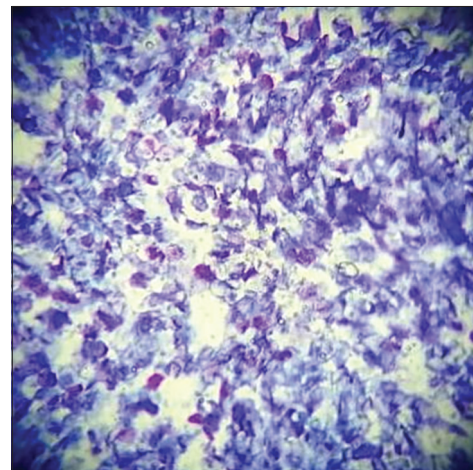


Figure 2: Fine needle aspiration cytology slide using the May-Grunwald Giemsa staining method at $\times 10$ magnification. Micrograph showing nucleated and anucleated squamous cells along with degenerated cells and keratin debris

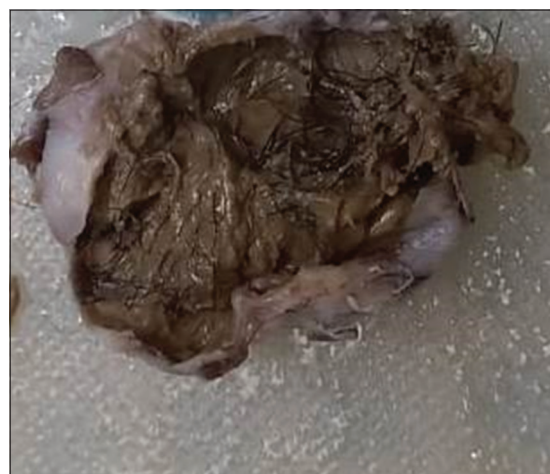

Figure 3: Excised cyst showing pultaceous material along with hair tuft inside the cyst cavity

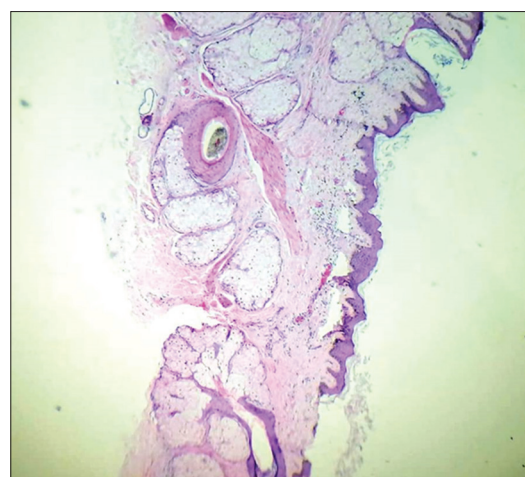


Figure 4: Histopathology slide using hematoxylin and eosin staining method at $\times 10$ magnification examinations. Micrograph showing the pilosebaceous unit, stratified squamous epithelium, and keratin debris

of DCs: (a) there is congenital inclusion of dermal and epidermal elements of germ layers in deeper tissues along the embryonic

lines of fusion, (b) implantation of dermal and epidermal elements of surface epithelium which may proliferate and keratinize after birth due to trauma [2].

DC is usually present in the gonads, followed by extragonadal DC along the median and para-median sites of the body. The congenital facio-maxillary DCs are formed by entrapment of ectodermal components between the first and second branchial arch in the embryonic period. Postauricular involvement is extremely rare, thus making clinical diagnosis uncertain [6]. Mostly, patients with postauricular DCs present with a painless swelling in the retroauricular region, however, the swelling may become painful if inflammation occurs. Due to the unnoticeable location and painless nature of DC, most of the patients seek medical care when the cyst has enlarged significantly and for cosmetic reasons [6-8]. In our case, the swelling was noticed by a doctor for examination of another ailment.

The use of different radiological methods can help to narrow down the diagnosis. USG is one of the initial modalities for diagnosis that is without radiation exposure, rapid, and economical. USG of DC demonstrates a well-defined homogenous and hypoechoic cystic lesion. Computed tomography imaging is useful for delineating the changes in bony erosions and for radiological confirmation. Magnetic resonance imaging is the preferred means of revealing evidence of any intracranial extension [2]. FNAC can differentiate the DC from other lesions, such as sebaceous cyst, lymphadenopathy, lipoma, and hemangioma and thus narrow down the diagnosis further [9].

The recommended treatment of choice for DCs in any location is surgical excision. Early surgical intervention gives better cosmetic outcomes, prevents complications, and establishes diagnosis. Excision of the cyst is done meticulously for removal of the entire cyst wall. Complete surgical excision with removal of cyst wall and contents is essential to prevent any complication and recurrence. The recurrence rate for an infected cyst following excision can be as high as 20%. It is therefore important that asymptomatic cysts should be completely excised [2,10,11]. Diagnosis of the DC is established by HPE. HPE shows a well-defined wall lined by stratified squamous epithelium and mature skin appendages (hair follicles and sebaceous glands) with a lumen filled with keratin and hair shafts [2]. In our case, histopathology confirmed the diagnosis of the DC with no malignant transformation. In the head-and-neck region, the overall prognosis of DC is excellent, especially when no intracranial or intraspinal extension is present and no malignant change is there. Malignant transformation of a DC is very rare; however, it has been reported [12]. DCs are rare in the head and neck and exceptionally rare posterior to the auricle with only a handful of cases described in the recent literature [4,13,14].

CONCLUSION

Head-and-neck DCs are often present since childhood and are exceptionally rare posterior to the auricle. They may be congenital

or acquired. Common differential diagnoses include epidermoid cysts, sebaceous cysts, lipomas, and retroauricular lymph nodes. Clinically, they lie dormant for a time span and then grow because of enlargement, rupture, or sometimes extend into surrounding structures. Imaging modalities help narrow down the diagnosis and rule out any intracranial extension. Complete excision at an early stage is required to avoid recurrence, infection, rupture, and malignant change, and for cosmetic purposes. A HPE is required for confirmation and to rule out any malignant change. Although extremely rare, DC should be considered in the differential diagnosis of postauricular lumps.

ACKNOWLEDGMENT

The authors thank all those who were directly or indirectly involved in the management of this case.

REFERENCES

1. Zhao D, Han Y, Chen Y, Qiu J. An unusual dermoid cyst in subcutaneous tissue of the mastoid region: A case report. *Exp Ther Med* 2013;6:75-6.
2. Regmi A, Speiser J. Dermoid Cyst. Available from: <https://www.pathologyoutlines.com/topic/skintumornonmelanocyticdermoidcyst.html> [Last accessed on 2024 Aug 06].
3. Batsakis JG. Tumors of the Head and Neck: Clinical and Pathological Considerations. United States: Lippincott Williams and Wilkins; 1979. p. 144-75.
4. Jeong J, Choi YJ, Lee K, Choi HS. Dermoid cyst in the postauricular area. *J Craniofac Surg* 2020;31:e664-5.
5. Jham BC, Duraes GV, Jham AC, Santos CR. Epidermoid cyst of the floor of the mouth: A case report. *J Can Dent Assoc* 2007;73:525-8.
6. Cho Y, Lee DH. Clinical characteristics of idiopathic epidermoid and dermoid cysts of the ear. *J Audiol Otol* 2017;21:77-80.
7. Al-Khateeb TH, Al-Masri NM, Al-Zoubi F. Cutaneous cysts of the head and neck. *J Oral Maxillofac Surg* 2009;67:52-7.
8. Mohammed A, Abdullahi K. Postauricular epidermoid and dermoid cysts in adults. *Egypt J Otolaryngol* 2018;34:213-6.
9. De Souza BA, Dey C, Carver N. A rare case of dermoid cyst behind the ear. *Plastic Reconstr Surg* 2003;112:1972.
10. Han HH, Ju RK, Seo BF, Moon SH, Oh DY, Ahn ST, *et al.* Dermoid cyst excision under müller muscle in a patient with blepharoptosis. *Arch Plast Surg* 2014;41:607-9.
11. Dabholkar JP, Patole AD, Sheth AS, Saaj R. Congenital cystic lesions in head and neck. *Indian J Otolaryngol Head Neck Surg* 2003;55:128-30.
12. Orozco-Covarrubias L, Lara-Carpio R, Saez-De-Ocariz M, Duran-Mckinster C, Palacios-Lopez C, Ruiz-Maldonado R. Dermoid cysts: A report of 75 pediatric patients. *Pediatr Dermatol* 2013;30:706-11.
13. Alberici MP, Franzini S, Tassi S, Di Lella F, Negri M. Dermoid cyst of the retroauricular region: A rare clinicopathological entity. *Acta Biomed* 2021;92:e2021075.
14. Aljeaid D, Alharthi A, Alotaibi O, Altalhi W. Postauricular dermoid cyst: A rare lesion in an extremely rare location. *Egypt J Otolaryngol* 2022;38:92.

Funding: Nil; Conflicts of interest: Nil.

How to cite this article: Khan S, Singla V, Chaudhary G, Sheoran C. Postauricular dermoid cyst: A very rare clinicopathological entity. *Indian J Case Reports*. 2025; 11(1):8-10.